



Summary Feedback

(Combined feedback broadcasted at multiple times this week)

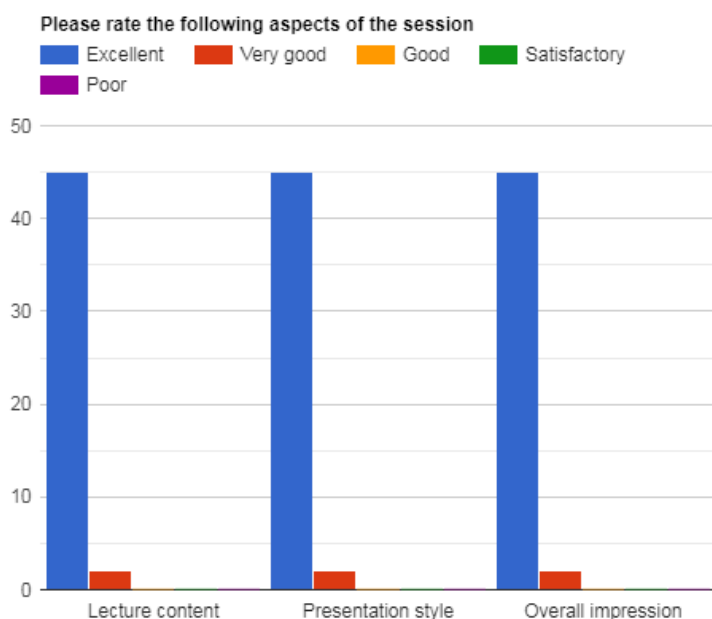
PRE - RECORDED ST1-ST4 Teaching Programme 2023

GIT - (1) Hepatobiliary (Part 2), Pancreas & Spleen (2) Role of CT in Staging of Pancreatic Carcinoma (26th and 27th August 2023)

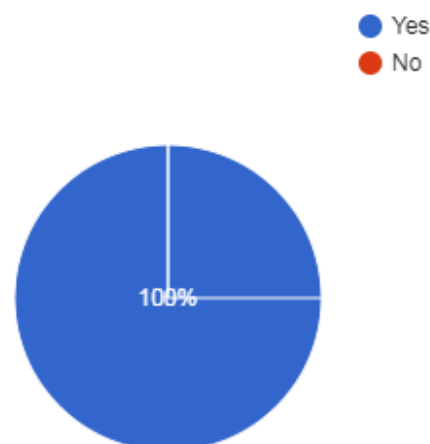
Lecturer: Sami Khan

Summary Points:

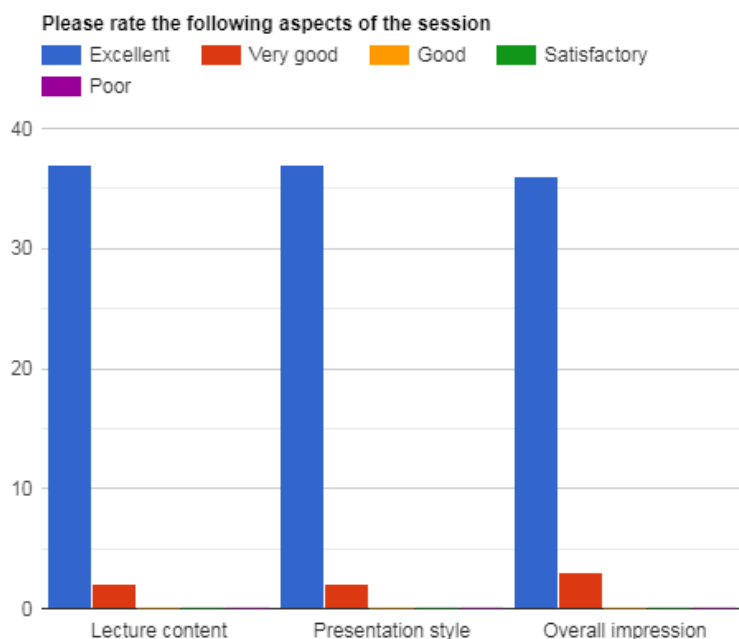
- Total Attendees: 285 from 29 Countries (Algeria, Bahrain, China, Czech Republic, Dominica, Egypt, India, Indonesia, Iraq, Jordan, Kenya, Malaysia, Myanmar, Nepal, Nigeria, Oman, Pakistan, Qatar, Saudi Arabia, Singapore, South Africa, Sri Lanka, Sudan, Türkiye, UAE, UK, Yemen, Zambia, Zimbabwe).
- Total duration: 3 hours (each session broadcasted thrice during the week)
- Total feedback received from 98 participants, from three different broadcasts



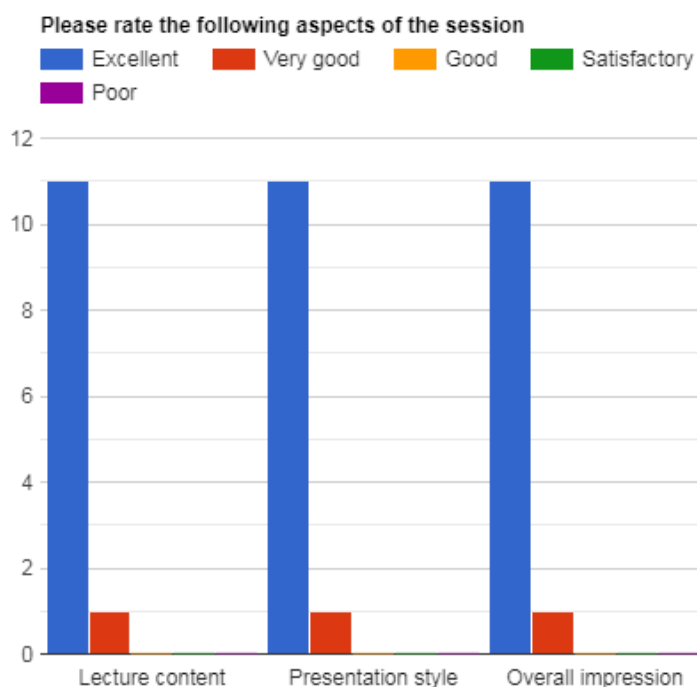
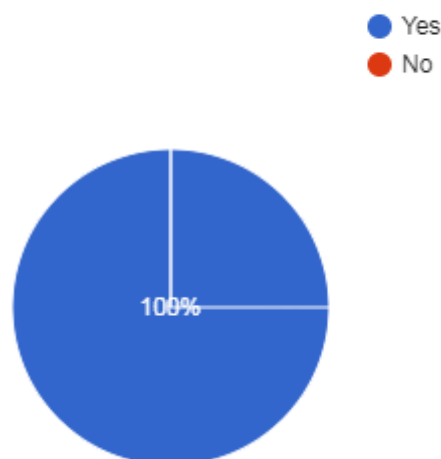
Did you find it useful
47 responses



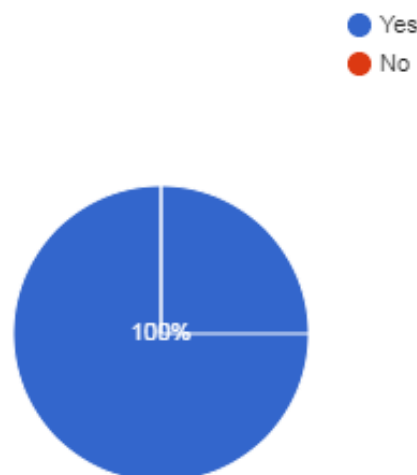
GIT - (1) Hepatobiliary (Part 2), Pancreas & Spleen (2) Role of CT in Staging of Pancreatic Carcinoma



Did you find it useful
39 responses



Did you find it useful
12 responses



Testimonials

- Dr Khan is an excellent teacher, pointing out useful tips for radiology practice and exams too (UK).
- Excellent session as always by a brilliant teacher. We owe all our knowledge of radiology to you sir that's a lot for always teaching with full dedication and utmost interest to guide us for the exams as well as normal day to day work scenarios (Pakistan).
- Superb session (India).

GIT - (1) Hepatobiliary (Part 2), Pancreas & Spleen (2) Role of CT in Staging of Pancreatic Carcinoma

- More than excellent I have ever attended (Saudi Arabia).
- Learning the pathology and differentials involving the pancreas was useful. It was excellent consolidation of reading that I did this week from Core Radiology, and seeing actual cases helps with memory (UK).
- Excellent teaching session (Algeria).
- Amazing session, very useful and comprehensive. Thank you so much! (UK).
- Excellent lecture and brilliant delivery (Nigeria).
- Awesome session (Indonesia).
- Very impressive good data organized and how to think to reach diagnosis is fantastic (Qatar).
- Excellent. 2nd to none (UK).
- Best of best (India).
- Excellent lecture (Algeria).
- Very good quality of video recording thank you (UK).
- I liked the cases selection and discussion (UAE).
- Clear concepts (Pakistan).
- Every aspect is useful (UK).
- Nice extensive explanation with amazing examples (Bahrain).
- Images and lecture are superb (Pakistan)
- Every single word of the session was useful (Pakistan).
- Excellent session (Pakistan).
- I liked the detailed explanation (Pakistan).
- I liked the PACS cases and the lecture (Algeria).
- Teaching material and method was amazing (UAE).
- God bless you sir (UAE).
- The interactive session (Pakistan).
- Excellent session (UK).
- Great teaching (Pakistan).
- Excellent session (India).
- Best session (Pakistan).
- Fantastic (Pakistan).
- I liked various presentations of hepatobiliary system (India).
- Simple description (Sri Lanka).
- Cases explanation was superb (Egypt).
- Conceptual teaching with interactive session (India).
- Superb session (Pakistan).
- Many cases with different findings were used to drive home the essential points (Nigeria).
- Very educative (Nigeria).
- Best (Pakistan).
- All contents are excellent (Saudi Arabia).
- Nice (Pakistan).
- Useful session (Pakistan).
- Clear picture and demonstration of pathology/sign was useful (Pakistan).
- Great (UK).
- Clear concepts (Pakistan).
- Images and lecture were amazing (Pakistan).

GIT - (1) Hepatobiliary (Part 2), Pancreas & Spleen (2) Role of CT in Staging of Pancreatic Carcinoma

- Cases with theory and anatomy completing all the aspects (Pakistan).
- Best session (Pakistan).
- I liked the case based discussions (Zambia).
- Very well done (Pakistan).
- Thank you a lots (Yemen).
- Awesome (Pakistan).

Biliary Strictures : Differential Based on Level

Exam Tip

Proximal

1. Cholangiocarcinoma
2. Porta hepatis Mets
3. GB Carcinoma

Middle

1. Cholangiocarcinoma
2. Pancreas Carcinoma

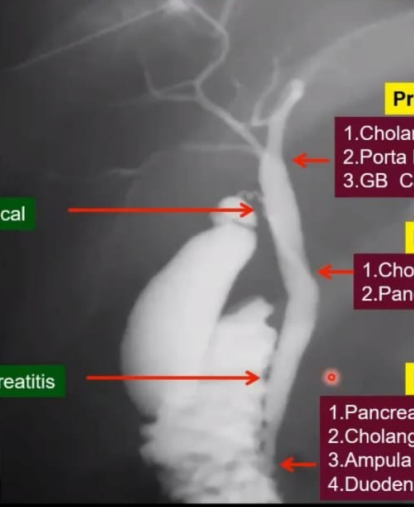
Distal

1. Pancreas Carcinoma
2. Cholangiocarcinoma
3. Ampula of Vater Carcinoma
4. Duodenal Carcinoma

Post Surgical

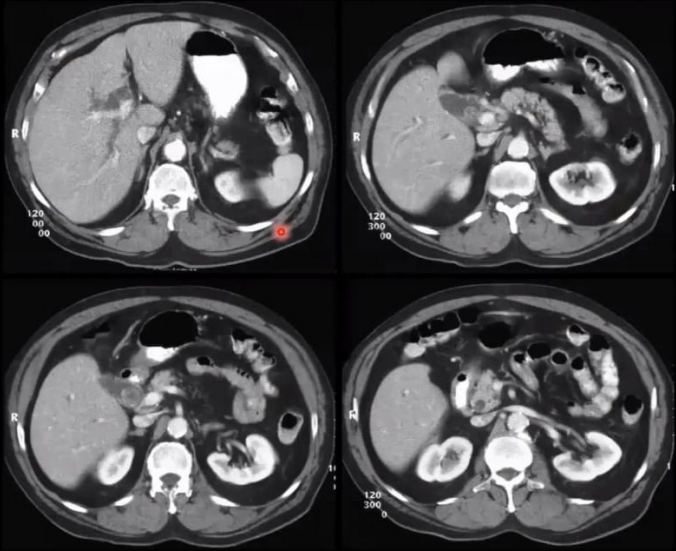
Chronic Pancreatitis

Dr Khan's Teaching's screen



Viva

Dr Khan's Teaching



120 300 00

120 300 00

120 300 00


120 300 00

ACR

1/2

EXAM TIP : Signs of Vascular Invasion

Oesophageal Carcinoma



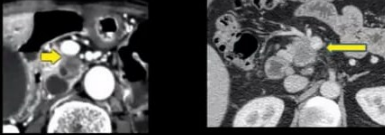
Contact with Descending Aorta

1. Less than 45 Degree : Not involved
2. Between 45-90 Degree : Doubtful
3. More than 90 Degree : Probable


Accuracy of 80% in determining aortic involvement

Pancreatic Carcinoma

Two different cases: <math><180^\circ</math> Vessel encasement



Two different cases: >math>>180^\circ</math> Vessel encasement



Dr Khan's Teaching

=====XX=====XX=====